Ref: Ro J Infect Dis. 2020;23(2)
DOI: 10.37897/RJID.2020.2.15

# "To be or not to be": How real is the diagnosis of COVID-19 infection

**Sorin Bivolaru[1,2], Oana Cristina Voinea[3], Manuela Arbune[1,4]**

[1]Faculty of Medicine and Pharmacy, "Dunarea de Jos" University, Galati, Romania
[2]"Dr. Aristide Serfioti" Military Emergency Hospital, Galati, Romania
[3]Medico-Military Scientific Research Center, Bucharest, Romania
[4]Clinical Hospital for Infectious Diseases, Galati, Romania

## ABSTRACT

The pandemic COVID-19, consecutive of the new SARS-CoV-2 coronavirus, reveals large variability, both in terms of severity and forms of clinical manifestation. We present the case of a young patient, with respiratory syndrome associated with fever, dermatological and neurological manifestations, related to imaging features compatible with COVID-19 infection. The test RT-PCR SARS-CoV-2 remained negative in two distinct samples, but convalescent serological tests were positive for IgG-coronavirus, suggesting this etiology. In conclusion, pulmonary imaging, corroborated with clinical manifestations and epidemiological data, could disclose the diagnosis of COVID-19 infection, although RT-PCR SARS-CoV-2 is the standard test for confirmation. The use of serological tests for diagnosis should be used in cases with high clinical suspicion and negative RT-PCR SARS-CoV-2 results, in order to increase the identification rate of acute infections and to limit the spread of infection.

**Keywords:** COVID-19, „ground glass" image, maculopapular rash, false negative RT-PCR SARS-CoV-2

## INTRODUCTION

COVID-19 infection related to the new coronavirus SARS-COV-2 is characterized by rapid spread, potential severe evolution and high mortality associated with severe acute respiratory syndrome, sepsis, coagulation disorders or „cytokine storm".

Due to the variability of clinical manifestations and the increased proportion of asymptomatic cases, the diagnosis criteria should not be limited to the clinical picture (1). The diagnosis of COVID-19 is based on the epidemiological history, clinical symptoms, imagistic criteria and is confirmed by the viral detection by polymerase chain reaction (PCR) techniques (2).

Rigorous analysis of each case can help understand this emerging pandemic infection.

## CASE PRESENTATION

A 38-year-old man from the urban area, non-smoker, with a history of drug allergies (aspirin, ibuprofen) and multiple surgeries for bilateral kidney stones, has presented to the emergency department for fever, chills, chest pain and cough.

The onset of disease was 10 days ago, with arthralgias of the large joints, pains of the limbs, mainly localized to the tendon, accompanied by difficulties in routine movements, such as orthostatic lifting or climbing stairs. Those symptoms recovered after 3 days, by using anti-inflammatory local applications. Physical asthenia and appetite loss have also marked the onset and gradually increased during the following days. In the fourth day of the disease, a maculo-erythematous rash characterized by inhomogeneous

*Corresponding author:*
Prof. Manuela Arbune, MD, PhD
*E-mail:* manuela.arbune@ugal.ro

*Article History:*
Received: 31 May 2020
Accepted: 20 June 2020

round-oval lesions with various sizes, non-confluent, non-pruritic, and negative vitropressure test, appeared distal in the both legs, interesting either the dorsal and the plantar foots (Figure 1). These lesions evolved for 3 days and have completely recovered without treatment.

***FIGURE 1.*** *Maculo-papular lesions associated with COVID-19*

From the 8th day of illness, the general condition worsened, with exacerbated asthenia, appearance of the night sweats and low fever episodes, accompanied by muco-purulent and blood-streaks rhinorrhea and cough (Figure 2).

From the 9-th day, the fever increased to 38.9˚C, associated with chills, severe cough, anterior chest pains, balance disorders and paresthesia of the lower limbs. No improvement was achieved after self-medication with acetaminophen.

The emergency medical examination in the 10th day of illness, revealed a middle influence of the general condition, normal conscious state, no meningeal or focal neurological signs, no rash, but severely sweaty skin and 5% weight loss were recorded. There were noted: body temperature 37.4˚C, blood pressure (BP) 120 / 80 mmHg, heart rate (HR) 88 /min, respiratory rate (RR) 24/min, peripheric oxygen saturation ($SO_2$) 97% and uncharacteristic pulmonary auscultation.

Clinical data were suggestive for an acute infectious respiratory febrile disease, considering the viral and atypical bacteria as the main differential diagnosis.

Laboratory investigations were normal, excepting for moderate increase of the erythrocytes sedimentation rate (ESR).

The computed tomography of the thorax (TCT) was performed and it revealed pulmonary foci with "ground glass" appearance and alveolar lesions, some of them with nodular character, that were distributed bilateral, mainly basal. Additionally, bilateral discrete pleural effusion (Figure 3). Abdominal CT was normal, except the microlithiasis and mild diffuse hepatosplenomegaly.

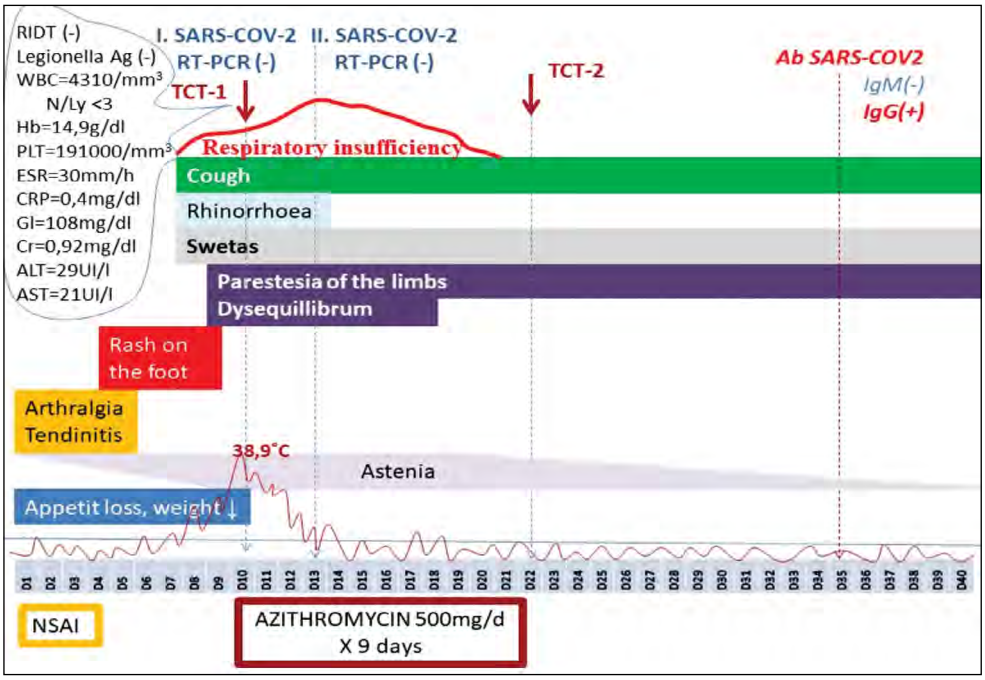


***FIGURE 2.*** *Evolution of probable COVID-19 infection*

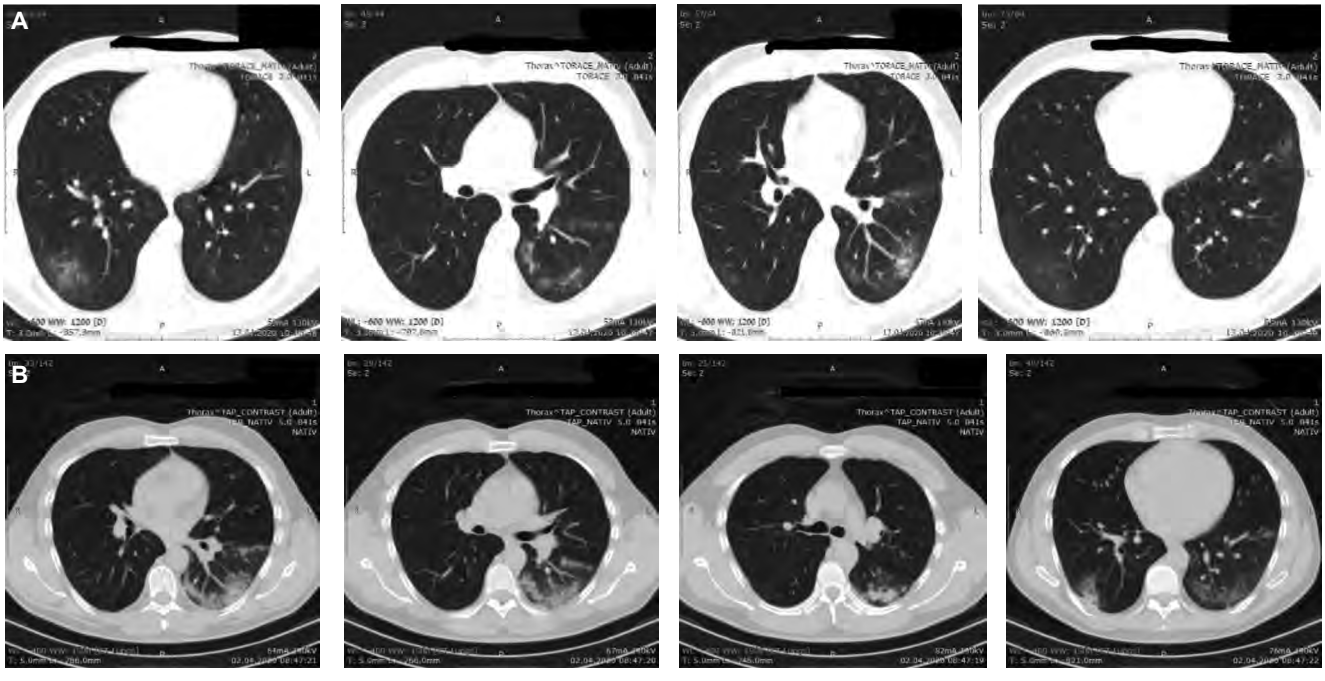


***FIGURE 3.*** *Thoraco-pulmonary computed tomography native (A) and contrast (B) – Multifocal infiltrates with "ground glass" appearance in the left inferior lobe associated with diffuse unsystematized nodular alveolar foci, predominantly subpleural basal posterior; "ground glass focus "with nodular area of adjacent alveolation in the inferior right lobe, located peripheral in the lateral basal segment; minimal bilateral pleural effusion*

Rapid tests for influenza virus and urinary Ag for *Legionella spp.* were negative.

No link to a suspected or confirmed case was identified. However, considering the ongoing epidemic, the RT-PCR SARS-CoV-2 test from the nasopharyngeal secretions was performed. The result was negative, but a high degree of suspicion for SARS-CoV-2 remained, due to the pulmonary CT findings. The treatment with Azithromycin was decided.

After the 12th day, the fever decreased, although the frequency and intensity of dyspnea got worse and required hospital care. The examination revealed normal body temperature, although there were mentioned RR 28/min, $SO_2$ 88% and HR 135/min. Except of tachycardia, no other abnormal EKG data were found. The test RT-PCR-SARS-CoV-2 was repeated on the day 13, and the result was still negative. Based on the available data, the diagnosis was: „*Atypical bilateral pneumonia with alveolar multiple foci and pleural effusion. Clinical and imaging suspicion of COVID-19 infection, with negative viral test for SARS-CoV-2".*

After discharge, treatment with Azithromycin 500 mg/day was ongoing until the day 18, when respiratory dysfunction and exercise tolerance were improved.

The TCT was repeated after the 3rd week, and was concordant with the clinical improvement, because of 40% decreasing of the initial described opacities (Figure 3).

After 5 weeks, the medical exam noted slight dry cough, persistent cold and profuse nocturnal sweats and improved but incomplete recovered tolerance to effort. The serologic test for SARS-CoV-2 was positive for IgG Ab and negative for Ab IgM.

## DISCUSSIONS

The dilemma of this case is still present: was it a COVID-19 infection or not?

Considering the context of the COVID-19 pandemic, the febrile syndrome associated with respiratory dysfunction and imaging changes of "ground glass", the etiology of SARS-CoV-2 has a high probability, although it was not confirmed by the standard diagnostic virologic test.

Using high accuracy and rapid tests for identification of the new SARS-CoV-2 coronavirus is crucial for the early diagnosis of COVID-19 infection and the epidemiological control of infectious sources. Serological tests are valuable for the epidemiological studies and for the evaluation of asymptomatic infections. Although these tests are not recommended for the diagnosis of acute disease, a recent study proved the presence of IgM and IgG antibodies beginning with

the 5 days after onset. Therefore, the serologic tests should be usefulness for the diagnostic of patients with false negative PCR results, when inadequate collection of the respiratory secretions or inadequate testing technique (3). However, the significance of a positive result may be questionable, given the possibility of cross-reactions with other respiratory coronaviruses (4).

The polymerization chain reaction (PCR) method is considered the "gold standard" for laboratory diagnosis of viral infections. The "Real-Time" variant (RT-PCR) is the most used investigation for the detection of SARS-CoV-2, due to the simplicity of the method, as to the high sensitivity and specificity (5).

The results of RT-PCR could be influenced by the genetic diversity and rapid evolution of the new coronavirus, reported by several studies (6).

Although several types of kits have been developed for the diagnosis of RT-PCR SARS-CoV-2, the mutations of the viral genome explain the false-negative results, through the mismatch between viral sequences and complementary primers. Additionally, the dynamics of viral load is different from other previous known coronaviruses and varies from one patient to another, but also depending on the biological product thar was evaluated (3).

Therefore, the negative result RT-PCR for SARS-CoV-2 does not exclude the infection, especially if nasopharyngeal respiratory secretions are tested and if characteristic imaging of COVID-19 are present on CT examination (7).

The high value TCT images for the diagnosis of COVID-19 infection is considered when there are found "ground glass" appearances, mainly peripheral and subpleural distribution, involving multiple lobs, especially the lower lobes, sometimes associated with focal consolidation areas. However, "ground glass" lesions are not specific for COVID-19 and could be also associated to other conditions, such as severe influenza, or pneumonia related to cytomegalovirus, syncytial respiratory virus, *Mycoplasma pn., Chlamydia pn., Pneumocystis jiroveki* (8).

The reticular appearance of COVID-19 pneumonia is developed after the 2nd week of evolution, as indicator of irreversible fibrosis, that requires long-term follow up (9).

Although the clinical form of the case is defined by the main pneumonic involvement, the course of disease was peculiar, due to the eruptive syndrome in the first week and a neurological syndrome expressed with balance disorders and limb paresthesia.

COVID-19-associated skin lesions were classified into five categories: maculopapular rash, urticaria, vesicular rash, pseudo-frostbite, and livedo or necrosis. They are rarely occurring before the onset of other symptoms and are usually mentioned concomitant with clinical course or later in the course of the disease. In a series of 375 cases with dermatologic manifestations associated to COVID-19 infections, the frequency of the maculopapular lesions was 47%. The majority cases of maculopapular rash occurred concomitantly with other symptoms and were accompanied by severe evolution (10).

The allergic history of the present case and the appearance of the rash before the specific respiratory manifestations contributed to the difficulties in the dermatological diagnosis.

The neurological disorders associated to COVID-19 have been reported in several studies, especially in severe cases. Headache and dizziness are the most common manifestations, that are reported with variable frequency, ranging between 3 and 12%. Both the central nervous system and the peripheral nervous system are involved. The neurological impairment is the consequence of two main identified pathological mechanisms, by hypoxic brain damage or by immunologically mediated damage (11).

Over more, experimental studies suggested the neuroinvasive potential of the virus, by entering directly into the brain along the olfactory nerves, then by binding to ACE2 receptors of the glial cells and spinal neurons and consequent neuronal damaging (12).

## CONCLUSIONS

Non-respiratory manifestations during COVID-19 infection were rarely reported and contribute to the difficulty of this diagnosis. Pulmonary imaging, corroborated with clinical manifestations and epidemiological data, could disclose the diagnosis of COVID-19 infection, although RT-PCR SARS-CoV-2 is the standard test for confirmation. The serological tests for diagnosis should be used in cases with high clinical suspicion and negative RT-PCR SARS-CoV-2 results, in order to increase the identification rate of acute infections and to limit the spread of infection.

## REFERENCES


1. Tahamtan A, Ardebili A. Real-time RT-PCR in COVID-19 detection: Issues affecting the results. *Expert Rev Mol Diagn.* 2020;20(5):453-454.
2. Corman VM et al. Detection of 2019 novel coronavirus (2019-nCoV) by real-time RT-PCR. *Euro Surveill.* 2020;25(3):2000045.
3. Loeffelholz MJ, Tang YW Laboratory diagnosis of emerging human coronavirus infections – the state of the art. *Emerg Microbes Infect.* 2020; 9(1):747-756.
4. Long Q, Liu B, Deng H et al. Antibody responses to SARS-CoV-2 in patients with COVID-19. *Nat Med,* 2020.
5. Shen M, Zhou Y, Ye J et al. Recent advances and perspectives of nucleic acid detection for coronavirus. *J Pharm Anal.* 2020.
6. Shen Z, Xiao Y, Kang L et al. Genomic diversity of SARS-CoV-2 in Coronavirus Disease 2019 patients. *Clin Infect Dis.* 2020:ciaa203 [ahead of print].
7. Wang Y, Kang H, Liu X, et al. Combination of RT-qPCR testing and clinical features for diagnosis of COVID-19 facilitates management of SARS-CoV-2 outbreak. *J Med Virol.* 2020 [ahead of print].
8. Wang Y, Dong C, Hu Y , Li C, Ren Q, Zhang X et al. Temporal changes of CT findings in 90 patients with COVID-19 pneumonia: A longitudinal study. *Radiology,* 2020.
9. Hu Q, Guan H, Sun Z et al. Early CT features and temporal lung changes in COVID-19 pneumonia in Wuhan, China. *Eur J Radiol.* 2020;128:109017 [ahead of print].
10. Galván Casas C, Català A, Carretero Hernández G et al. Classification of the cutaneous manifestations of COVID-19: A rapid prospective nationwide consensus study in Spain with 375 cases. *Br J Dermatol.* 2020 [ahead of print].
11. Ahmad I, Rathore FA. Neurological manifestations and complications of COVID-19: A literature review. *J Clin Neurosci.* 2020.
12. Baig AM, Khaleeq A, Ali U, Syeda H. Evidence of the COVID-19 virus targeting the CNS: tissue distribution, host virus interaction, and proposed neurotropic mechanisms. *ACS Chem Neurosci.* 2020;11(7):995-998.


*Conflict of interest:* none declared
*Financial support:* none declared